

Clinical Communications

Leukocyte adhesion deficiency-I: A comprehensive review of all published cases

Elena Almarza Novoa, PhD^{a,b,*},
 Sanchali Kasbekar, PharmD^{c,*},
 Adrian J. Thrasher, MD, PhD^d, Donald B. Kohn, MD^e,
 Julian Sevilla, MD, PhD^f, Tony Nguyen, MBA^g,
 Jonathan D. Schwartz, MD^{c,†}, and
 Juan A. Bueren, PhD^{a,b,†}

Clinical Implications

- Leukocyte adhesion deficiency-I (LAD-I) is a rare, serious disorder with severity determined by defective CD18 expression. LAD-I is characterized by umbilical complications, granulocytosis, and diverse infections. Severe LAD-I is frequently fatal before the age of 2 years without allogeneic transplant. We identified 323 cases published between 1975 and 2017.

TO THE EDITOR:

Leukocyte adhesion deficiency-I (LAD-I) is a rare disorder of leukocyte adhesion and migration, resulting from mutations in the *ITGB2* gene encoding for the β_2 -integrin component CD18. Deficiencies in CD18 prevent normal integrin dimerization and leukocyte adhesion to endothelial surfaces, processes essential to extravasation and antimicrobial activity.^{1,2}

Severe LAD-I (predominantly classified as <2% of CD18-expressing neutrophils) is characterized by recurrent, life-threatening bacterial and other infections and substantial infant mortality in patients who do not receive allogeneic hematopoietic stem cell transplant (HSCT). Mortality for severe LAD-I was reported as 75% by the age of 2 years in an initial 1988 multicenter retrospective evaluation.³ Most patients with moderate LAD-I (2%-30% CD18-expressing neutrophils) survive childhood, with recurrent infections of skin and mucosal surfaces; mortality by the age of 40 years reportedly exceeds 50%.³ LAD-I is also characterized by umbilical cord complications (delayed separation and omphalitis), impaired wound healing, and persistent leukocytosis.^{4,5}

Multiple reports have been published in recent decades; however, no comprehensive prognostic assessments are available subsequent to the 1988 report. We sought an updated understanding of severe LAD-I with emphasis on prognosis in the absence of HSCT, HSCT outcomes, and association of CD18 expression with clinical features. We created a database of all published LAD-I cases via PubMed searches and a review of additional references.

Three hundred twenty-three LAD-I cases were reported between 1975 and 2017 in 107 publications (68 of which were single case reports; largest series $n = 36$). The nations with the highest number of cases were Iran ($n = 65$), the United States ($n = 50$), and India ($n = 45$); the highest number of publications originated in the United States ($n = 25$) (see [Table E1](#) in

this article's Online Repository at www.jaci-inpractice.org for a comprehensive listing of publications and patient numbers by country and [Table E2](#) for a comprehensive listing of references).

Per investigator assessment, 113 patients were considered to have severe LAD-I, 63 moderate, and 147 not classified. Neutrophil CD18 expression was reported for 265 cases and was less than 2% in 135 patients (51%) and 2% or more in 130 patients (49%). Four patients with CD18 greater than or equal to 2% were considered to have severe LAD-I (CD18% range, 2.4-17.3). Sex information was available for 282 patients, of which 148 (52%) were males.

Age at presentation was reported for 146 cases. For 63 patients with CD18 less than 2%, median presentation was at age 1 month (range, 0.03-18 months); for 62 patients with CD18 of 2% or more, median presentation was at age 6 months (range, 0.03-192 months). HSCT was performed for 125 patients; 198 patients did not undergo HSCT.

Infections were described for 248 (77%) of the 323 cases; information regarding anatomic site and CD18% was specified in 154 cases (48%). The most frequent infections in 85 cases with CD18 less than 2% were respiratory tract (39%, including pneumonia), sepsis (29%), and otitis media (27%). The most frequent infections in 69 cases with CD18 of 2% or more were periodontal (52%, including gingivitis and oral ulcers), otitis media (36%), and sepsis (25%). Perianal skin infections and necrotic skin ulcers were each reported in more than 10% of the groups. For additional information, see [Table E3](#) in this article's Online Repository at www.jaci-inpractice.org.

Umbilical cord complications (delayed separation or omphalitis) were more frequent in patients with severe LAD-I, reported in 92 of 110 patients with CD18 less than 2% (84%) and 47 of 81 patients with CD18 of 2% or more (58%; $P = .0001$; χ^2 test). For the subset of patients with severe LAD-I with at least 2 years of follow-up (or death before the age of 2 years), there was significant correlation between absence of umbilical cord complications and survival to 24 months ($P < .001$; Fisher exact test). [Tables E4](#) and [E5](#) in this article's Online Repository at www.jaci-inpractice.org depict umbilical cord complication incidences and 2-year survival.

White blood cell (WBC) counts were reported in 143 cases (median, $45 \times 10^9/L$; range, $10-150 \times 10^9/L$). Although median WBC was higher in the group with CD18 less than 2% (48 vs $30 \times 10^9/L$), there was limited correlation between CD18 expression and WBC ($r < 0.1$) for the entire cohort and when the groups with CD18 less than 2% and of 2% or more were analyzed independently. Expression of β_2 -integrin heterodimers CD11a, CD11b, and CD11c was reported in 76, 89, and 69 cases, respectively. Correlations between CD18 and CD11 expressions were also limited ($r < 0.5$), consistent with a recent report.⁶ [Figures E1](#) and [E2](#) in this article's Online Repository at www.jaci-inpractice.org depict analyses regarding integrin expression and WBC.

Mutation analyses were provided for 139 cases; missense ($n = 34$) and frame shift ($n = 24$) mutations were most frequent for the subset ($n = 100$) in which these were characterized. More than 20 locations within the *ITGB2* gene were specified ($n = 120$); however, mutations on Exon 6 were most frequent

TABLE I. Survival to age of 2 y in absence of HSCT on the basis of clinical and laboratory assessments of LAD-I severity

LAD-I severity	N	Survival to age 2 y		
		Alive at ≥ 2 y	Follow-up to 2 y or death by 2 y	% alive to age 2 y
Severe: investigator assessment or CD18 $<2\%$	96	26	66	39%
Severe: CD18 $<2\%$	73	21	48	44%
Severe: CD18 $<2\%$ (2000-2017 only)	67	19	43	44%
CD18 2%-4%	17	9	13	69%
CD18 $>4\%$ -10%	25	18	19	95%
CD18 $>10\%$	36	29	29	100%

Many reports did not provide precise survival durations (stating only that mortality occurred before the age of 2 y), and hence it was not possible to generate Kaplan-Meier curves incorporating most of the severe LAD-I cases. Several patients were considered to have severe LAD-I despite CD18 expression on $>2\%$ neutrophils or unspecified CD18 expression; these cases are included in the top row in addition to those with CD18 expression on $<2\%$ neutrophils.

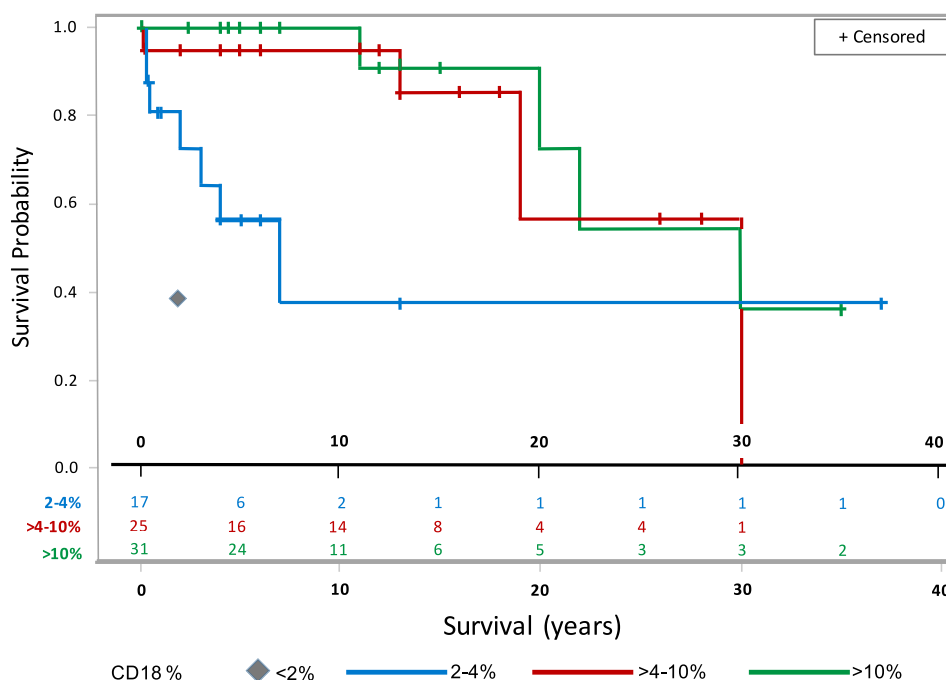


FIGURE 1. Kaplan-Meier survival estimates for patients with moderate LAD-I not receiving allogeneic HSCT, by CD18 expression. Because many reports did not provide precise survival (stating only that mortality occurred before the age of 2 years), it was not possible to generate plots incorporating most of the severe cases. The gray diamond indicates the 39% survival to the age of 2 years for 66 evaluable patients with severe LAD-I not receiving HSCT.

(24%) and mutations on Exons 5, 6, and 7 accounted for 44% of specified cases. We also identified 18 cases in which CD18 expression was more than 30% (range, 31%-99%). In 8 of 12 cases in which CD18 was more than 30% and CD11 information was available, at least 1 CD11 moiety was reported as less than 2%, consistent with recent descriptions of mutations enabling surface expression of nonfunctional CD18.⁶ Clinical and genetic details of these cases are provided in Table E6 of this article's Online Repository at www.jaci-inpractice.org.

We sought to understand whether prognosis for severe LAD-I in the absence of HSCT is similar to the initially reported 25% survival to the age of 2 years. There were 66 severe LAD-I cases (per investigator assessment or CD18 less than 2%) for whom survival to 2 years was reported, 40 of whom died before the age of 2 years (61% mortality). As indicated in Table I, survival to the age of 2 years was similar for severe LAD-I subsets defined

strictly by CD18 expression, and for severe cases reported since 2000. One patient with severe LAD-I survived beyond the age of 12 years (death at 13.5 years). Because many reports did not provide precise survival durations for severe LAD-I (stating only that mortality occurred before the age of 2 years), it was not possible to generate Kaplan-Meier plots incorporating most of the severe LAD-I cases. Survival to the age of 2 years and throughout early childhood exceeded 90% for patients with more than 4% CD18 expression. Figure 1 shows the survival probability for LAD-I cases on the basis of CD18 expression.

Outcomes for 101 patients receiving HSCT were consistent with recent series.^{7,8} Phenotypic correction was reported in 83% of HLA-identical sibling allograft recipients. Transplant-related mortality was 19% across all groups (11% for HLA-matched sibling recipients). Seven of 22 (32%) haploidentical recipients had HSCT-related mortality and 12 (55%) received at least 1

subsequent transplant. HSCT outcomes were not markedly different for cases in publications before 2000 ($n = 23$) versus those from 2000 to 2017 ($n = 78$), although the more recent interval included matched unrelated donor ($n = 24$) and cord blood ($n = 6$) transplants. Additional transplant information is provided in [Table E7](#) in this article's Online Repository at www.jaci-inpractice.org.

Our findings indicate that severe LAD-I remains a life-threatening condition with limited 2-year survival in the absence of allogeneic HSCT. Potential publication biases may include predilection for reporting more severe cases and those with favorable treatment outcomes; there is also potential underreporting from regions with higher disease incidence, in which LAD-I management is a component of regular practice. Umbilical cord complications and granulocytosis are frequent early LAD-I manifestations. Respiratory tract, ear, sepsis, oral, and skin infections are common. HSCT is the only available curative therapy; transplant-related mortality and other complications occur frequently, especially in haploidentical transplants. In addition to flow cytometry, genetic evaluation may confer meaningful diagnostic and prognostic information. Rapid identification of patients with potential LAD-I (unusual or severe infections during infancy, granulocytosis, and umbilical cord complications) is essential to enable referral to centers with disease expertise and early implementation of definitive therapy.

^aDivision of Hematopoietic Innovative Therapies, Centro de Investigaciones Energéticas Medioambientales y Tecnológicas (CIEMAT) and Centro de Investigación Biomédica en Red de Enfermedades Raras (CIBERER-ISCIIR), Madrid, Spain

^bAdvanced Therapies Unit, Instituto de Investigación Sanitaria Fundación Jiménez Díaz (IIS-FJD/UAM), Madrid, Spain

^cRocket Pharmaceuticals, New York, NY

^dInstitute of Child Health, Molecular and Cellular Immunology, University College London, Great Ormond Street Institute of Child Health, London, United Kingdom

^eUniversity of California Los Angeles, Los Angeles, Calif

^fPediatric Oncology Hematology and Stem Cell Transplant Department, Hospital Infantil Universitario Niño Jesús, Madrid, Spain

^gRTW Investments, New York, NY

^{*}These authors contributed equally to this work. [†]These authors contributed equally to this work.

Conflicts of interest: E. Almarza has received personal fees for lecturer participation and has patent licensing agreements for the development of LAD gene therapies from Rocket Pharmaceuticals. S. Kasbekar and J. D. Schwartz are full-time employees of Rocket Pharmaceuticals. A. Thrasher is a consultant for Rocket Pharmaceuticals. D. Kohn declares no relevant conflicts of interest. J. Sevilla serves as an advisory board member for Rocket Pharmaceuticals and has patent licensing agreements for the development of gene therapies from Rocket Pharmaceuticals. T. Nguyen is a full-time employee of RTW Investments and a stockholder of Rocket Pharmaceuticals. J. Bueren is a consultant for Rocket Pharmaceuticals, has patent licensing agreements for the development of LAD gene therapies from Rocket, and has also obtained financial support for research. Received for publication October 18, 2017; revised December 11, 2017; accepted for publication December 12, 2017.

Available online ■■

Corresponding author: Sanchali Kasbekar, PharmD, Rocket Pharmaceuticals, Regulatory Affairs, 430 East 29th St, New York, NY 10016. E-mail: sk@rocketpharma.com.

2213-2198

© 2017 The Authors. Published by Elsevier Inc. on behalf of the American Academy of Allergy, Asthma & Immunology. This is an open access article under the CC BY-NC-ND license (<http://creativecommons.org/licenses/by-nc-nd/4.0/>).

<https://doi.org/10.1016/j.jaip.2017.12.008>

REFERENCES

- Anderson DC, Schmalsteig FC, Finegold MJ, Hughes BJ, Rothlein R, Miller LJ, et al. The severe and moderate phenotypes of heritable Mac01, LFA-1 deficiency: their quantitative definition and relation to leukocyte dysfunction and clinical features. *J Infect Dis* 1985;152:668-89.
- Schmidt S, Moser M, Sperandio M. The molecular basis of leukocyte recruitment and its deficiencies. *Mol Immunol* 2013;55:49-58.
- Fischer A, Lisowska-Grospierre B, Anderson DC, Springer TA. Leukocyte adhesion deficiency: molecular basis and functional consequences. *Immunodef Rev* 1988;1:39-54.
- Hanna S, Etzioni A. Leukocyte adhesion deficiencies. *Ann NY Acad Sci* 2012;1250:50-5.
- Van de Vijver E, Van den Berg TK, Kuijpers TW. Leukocyte adhesion deficiencies. *Hematol Oncol Clin North Am* 2013;27:101-16.
- Levy-Mendelovich S, Rechavi E, Abuzaitoun O, Vernitsky H, Simon AJ, Lev A, et al. Highlighting the problematic reliance on CD18 for diagnosing leukocyte adhesion deficiency type 1. *Immunol Res* 2016;64:476-82.
- Qasim W, Cavazzana-Calvo M, Davies EG, Davis J, Duval M, Eames G, et al. Allogeneic hematopoietic stem-cell transplantation for leukocyte adhesion deficiency. *Pediatrics* 2009;123:836-40.
- Hamidieh AA, Pourpak Z, Hosseinzadeh M, Fazlollahi MR, Alimoghaddam K, Movahedi M, et al. Reduced-intensity conditioning and hematopoietic SCT for pediatric patients with LAD-1: clinical efficacy and importance of chimerism. *Bone Marrow Transplant* 2012;47:646-50.

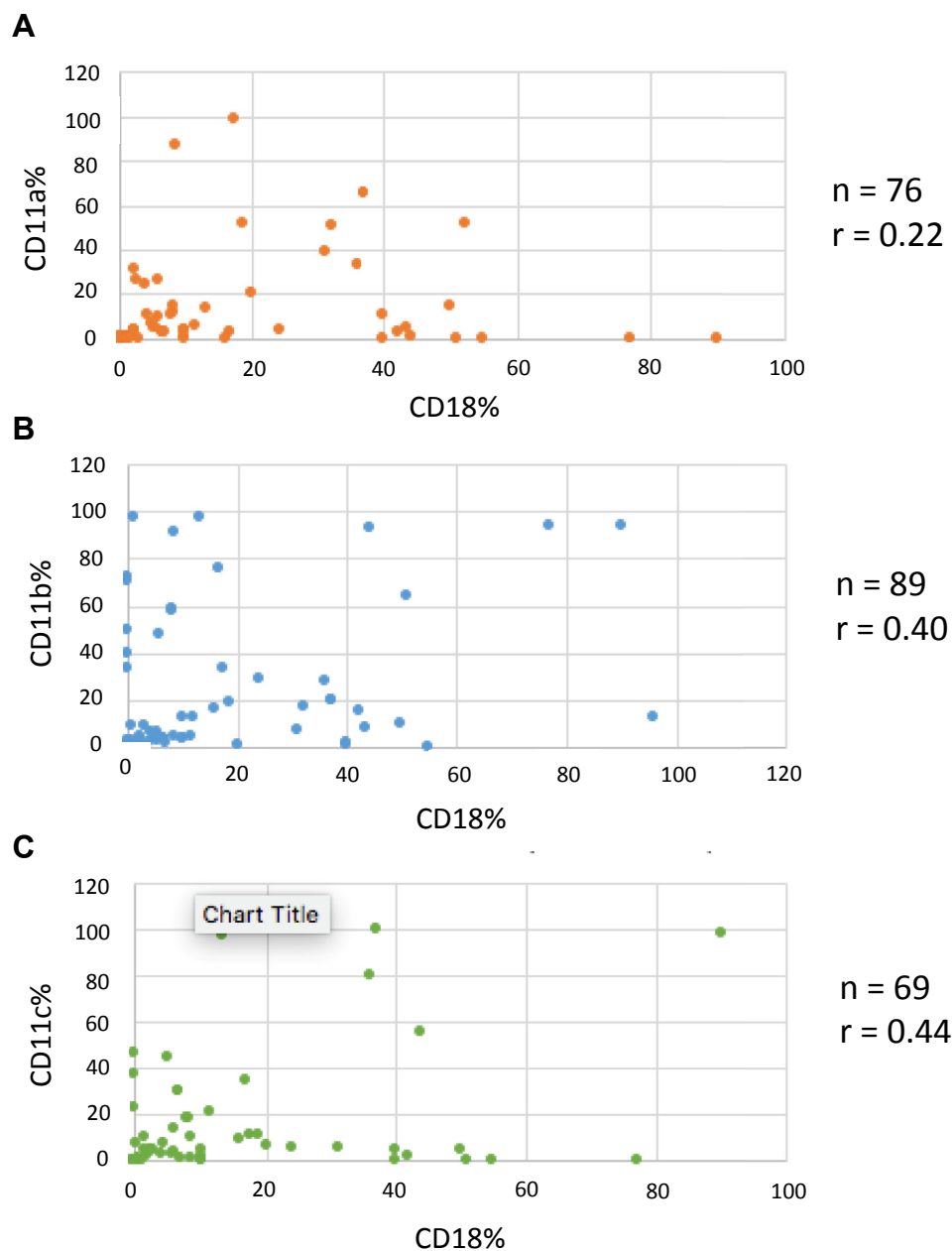


FIGURE E1. Correlation of neutrophil CD18 expression with β_2 -integrin heterodimer expression. CD18 expression by (A) CD11a, (B) CD11b, and (C) CD11c. Most publications did not provide precise mechanism by which β_2 -integrin expression was assessed; the percentage of neutrophils expressing CD18 (or CD11) via flow cytometry (relative to normal) is the most frequent modality for determination of CD18 expression.

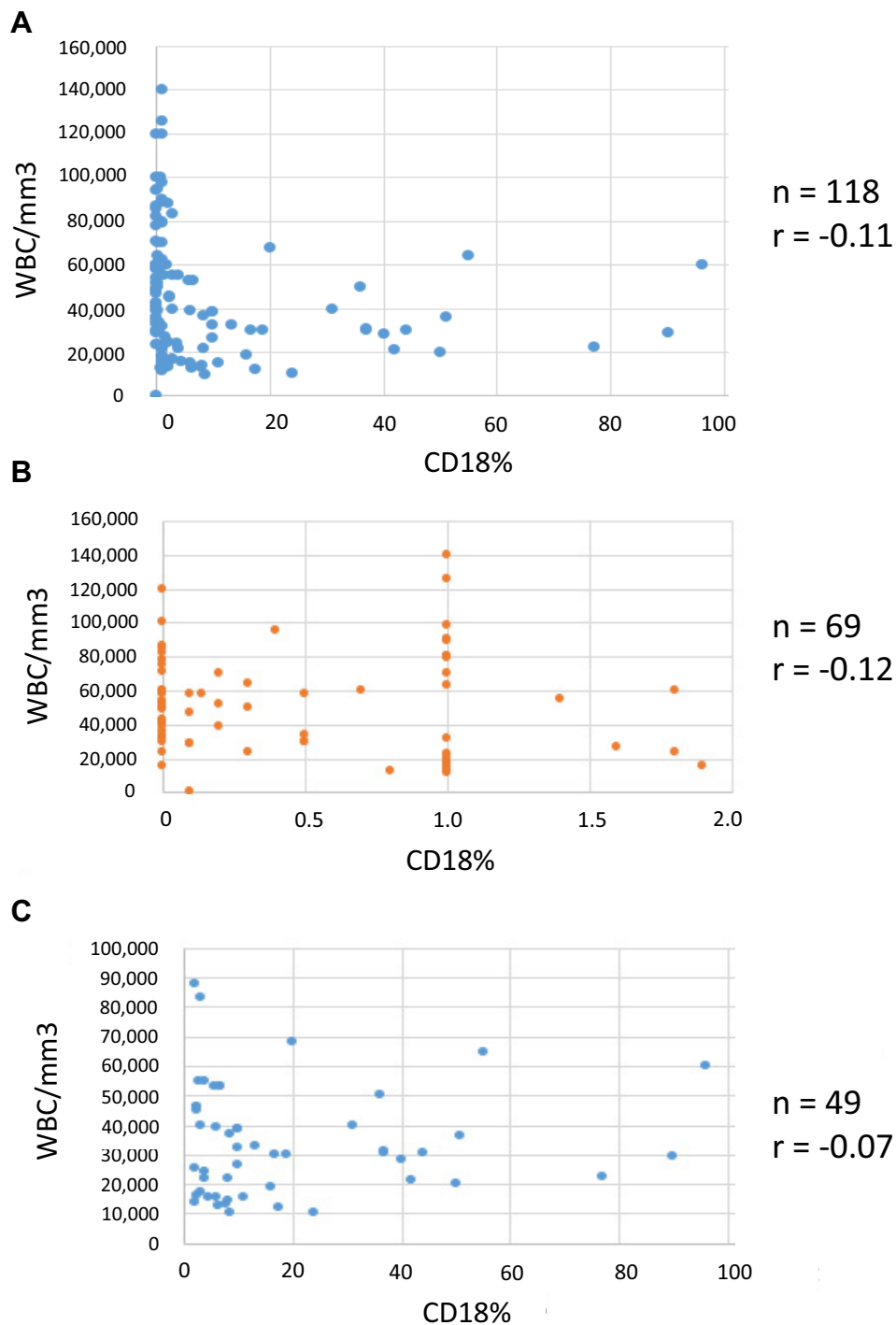


FIGURE E2. Correlation of neutrophil CD18 expression with highest reported WBC count for (A) all patients for whom information was reported, (B) patients with CD18 <2%, and (C) patients with CD18 ≥2%. Upper limits of normal for WBC counts vary between clinical laboratories, but are generally in the range of 9800/mm³.

TABLE E1. Publications and patient numbers by country

Country	No. of publications	No. of patients
United States	25	50
Iran	12	65
India	10	45
United Kingdom	8	16
The Netherlands	5	9
Japan	5	5
Italy	4	5
Mexico	3	4
Canada	3	5
France	3	6
Taiwan	3	2
Israel	2	12
Spain	2	2
European Union*	2	10
Saudi Arabia	2	13
Turkey	2	2
Chile	2	2
Jordan	2	2
Pakistan	2	3
United States/European Union*	1	36
Germany/France	1	14
Switzerland	1	4
Tunisia	1	5
Argentina	1	1
Brazil	1	1
Egypt	1	1
Norway	1	1
Singapore	1	1
China	1	1

*Publications with multiple contributing nations.

TABLE E2. LAD-I publications evaluated to comprise database

Reference	No. of cases
Akbari H, Zadeh MM. Leukocyte adhesion deficiency. <i>Indian J Pediatr</i> 2001;68:77-9.	1
Al-Dhekri H, Al-Mousa H, Ayas M, Al-Muhsen S, Al-Ghonaum A, Al-Ghanam G, et al. Allogeneic hematopoietic stem cell transplantation in leukocyte adhesion deficiency type 1: a single center experience. <i>Biol Blood Marrow Transplant</i> 2011;17:1245-9.	11
Alizadeh P, Rahbarimanesh AA, Bahram MG, Salmasian H. Leukocyte adhesion deficiency type 1 presenting as leukemoid reaction. <i>Indian J Pediatr</i> 2007;74:1121-3.	1
Allende LM, Hernandez M, Corell A, García-Pérez MA, Varela P, Moreno A, et al. A novel CD18 genomic deletion in a patient with severe leukocyte adhesion deficiency: a possible CD2/lymphocyte function-associated antigen-1 functional association in humans. <i>Immunology</i> 2000;99:440-50.	1
Al-wahadneh A, Haddadin I, Hamouri M, Omari K, Aejellat F. Bone marrow transplantation for leukocyte adhesion deficiency-I: case report. <i>Saudi J Kidney Dis Transpl</i> 2006;17:564-7.	1
Anderson DC, Schmalsteig FC, Finegold MJ, Hughes BJ, Rothlein R, Miller LJ, et al. The severe and moderate phenotypes of heritable Mac01, LFA-1 deficiency: their quantitative definition and relation to leukocyte dysfunction and clinical features. <i>J Infect Dis</i> 1985;152:668-89.	10
Anderson DC, Springer TA. Leukocyte adhesion deficiency: an inherited defect in the Mac-I, LFA-I, and pI50,95 glycoproteins. <i>Ann Rev Med</i> 1987;38:175-94.	10*
Arnaout MA, Pitt J, Cohen HJ, Melamed J, Rosen FS, Colten HR. Deficiency of granulocyte-membrane glycoprotein (gp150) in a boy with recurrent bacterial infections. <i>N Engl J Med</i> 1982;306:693-9.	1
Arshi S, Bahrami A, Faranoush M, Mehrvar A, Rezaei N. Non-Hodgkin's lymphoma in a patient with leukocyte adhesion deficiency. <i>Iran J Pediatr</i> 2014;24:31-2.	2
Bedlow AJ, Davies EG, Moss AL, Rebuck N, Finn A, Marsden RA. Pyoderma gangrenosum in a child with congenital partial deficiency of leukocyte adherence glycoproteins. <i>Br J Dermatol</i> 1998;139:1064-7.	1
Bissenden JG, Haeney MR, Tarlow MJ, Thompson RA. Delayed separation of the umbilical cord, severe widespread infections, and immunodeficiency. <i>Arch Dis Child</i> 1981;56:397-9.	1
Bowen TJ, Ochs HD, Altman LC, Price TH, Van Epps DE, Brautigan DL, et al. Severe recurrent bacterial infections associated with defective adherence and chemotaxis in two patients with neutrophils deficient in a cell, associated glycoprotein. <i>J Pediatr</i> 1982;101:932-40.	2
Buescher ES, Gaither T, Nath J, Gallin JI. Abnormal adherence-related functions of neutrophils, monocytes, and Epstein-Barr virus-transformed B cells in a patient with C3bi receptor deficiency. <i>Blood</i> 1985;65:1382-90.	1
Cabanillas D, Regairaz L, Deswarte C, García M, Richard ME, Casanova JL, et al. Leukocyte adhesion deficiency type 1 (LAD1) with expressed but nonfunctional CD11/CD18. <i>J Clin Immunol</i> 2016;36:627-30.	1
Castriconi R, Dondero A, Cantoni C, Della Chiesa M, Prato C, Nanni M, et al. Functional characterization of natural killer cells in type I leukocyte adhesion deficiency. <i>Blood</i> 2007;109:4873-81.	2
Cher BTH, Chan HS, Klein GF, Jabkowski J, Schadenböck-Kranzl G, Zach O, et al. A novel 3' splice-site mutation and a novel gross deletion in leukocyte adhesion deficiency (LAD)-1. <i>Biochem Biophys Res Commun</i> 2011;404:1099-104.	1
Chowdary S, Kumar M. Leukocyte adhesion defect: a rare cause of immunodeficiency. <i>Indian J Child Health</i> 2014;1:153-4.	1
Cox DP, Weathers DR. Leukocyte adhesion deficiency type 1: an important consideration in the clinical differential diagnosis of prepubertal periodontitis: a case report and review of the literature. <i>Oral Surg Oral Med Oral Pathol Oral Radiol Endod</i> 2008;105:86-90.	1
Crowley CA, Curnutte JT, Rosin RE, André-Schwartz J, Gallin JI, Klempner M, et al. An inherited abnormality of neutrophil adhesion: its genetic transmission and its association with a missing protein. <i>N Engl J Med</i> 1980;302:1163-8.	1
Dababneh R, Al-wahadneh AM, Hamadneh S, Khouri A, Bissada NF. Periodontal manifestation of leukocyte adhesion deficiency type I. <i>J Periodontol</i> 2008;79:764-8.	1
D'Agata, Paradis K, Chad Z, Bonny Y, Seidman E. Leukocyte adhesion deficiency presenting as a chronic ileocolitis. <i>Gut</i> 1996;39:605-8.	1
Davies EG, Isaacs D, Levinsky RJ. Defective immune interferon production and natural killer activity associated with poor neutrophil mobility and delayed umbilical cord separation. <i>Clin Exp Immunol</i> 1982;50:454-60.	2
Deist F, Blanche S, Keable H, Gaud C, Pham H, Descamp-Latscha B, et al. Successful HLA nonidentical bone marrow transplantation in three patients with the leukocyte adhesion deficiency. <i>Blood</i> 1989;74:512-6.	3

(continued)

TABLE E2. (Continued)

Reference	No. of cases
El-Sayed ZA, El-Ghoneimy DH, Abd-Allah H, Afifi HM. A rare association between leukocyte adhesion deficiency type I and psoriasis in humans. <i>Allergy Asthma Immunol Res</i> 2011;3:138-40.	1
Engel ME, Hickstein DD, Bauer TR Jr, Calder C, Manes B, Frangoul H. Matched unrelated bone marrow transplantation with reduced-intensity conditioning for leukocyte adhesion deficiency. <i>Bone Marrow Transplant</i> 2006;37:717-8.	1
Esmaili B, Ghadami M, Fazlollahi MR, Niroomanesh S, Atarod L, Chavoshzadeh Z, et al. Prenatal diagnosis of leukocyte adhesion deficiency type-1 (five cases from Iran with two new mutations). <i>Iran J Allergy Asthma Immunol</i> 2014;13:61-5.	4
Farinha NJ, Duval M, Wagner E, Champagne J, Lapointe N, Barrette S, et al. Unrelated bone marrow transplantation for leukocyte adhesion deficiency. <i>Bone Marrow Transplant</i> 2002;30:979-98.	3
Fathallah DM, Jamal T, Barbouche MR, Bejaoui M, Hariz MB, Dellagi K. Two novel frame shift, recurrent and <i>de novo</i> mutations in the ITGB2 (CD18) gene causing leukocyte adhesion deficiency in a highly inbred North African population. <i>J Biomed Biotechnol</i> 2001;1:114-21.	5
Fiorini M, Piovani G, Schumacer RF. ITGB2 mutation combined with deleted ring 21 chromosome in a child with leukocyte adhesion deficiency. <i>Allergy Clin Immunol</i> 2009;124:1356-8.	1
Fischer A, Descamps-Latscha B, Gerota I, Lisowska-Groszperle B, Gerota I, Perez N, et al. Bone-marrow transplantation for inborn error of phagocytic cells associated with defective adherence chemotaxis, and oxidative response during opsonised particle phagocytosis. <i>Lancet</i> 1983;2:473-6.	2
Garcia MB, Dominguez O, Juan M, Aróstegui JI, Badell I, Chapman E, et al. Type I leukocyte adhesion deficiency (LAD I): report of a case. <i>Allergol Immunopathol (Madr)</i> 2012;40:254-8.	1
Guneser S, Altintas DU, Aksungur P, Hergüner O, Sanal O. An infant with severe leukocyte adhesion deficiency. <i>Acta Paediatr</i> 1996;85:622-4.	1
Hamidieh AA, Pourpak Z, Alimoghaddam K, Movahedi M, Bahoush G, Behmanesh F, et al. Successful allogeneic stem cell transplantation with a reduced-intensity conditioning in a leukocyte adhesion deficiency type I patient. <i>Pediatr Transplant</i> 2009;15:E30-3.	1
Hamidieh AA, Pourpak Z, Hosseinzadeh M, Fazlollahi MR, Alimoghaddam K, Movahedi M, et al. Reduced-intensity conditioning and hematopoietic SCT for pediatric patients with LAD-1: clinical efficacy and importance of chimerism. <i>Bone Marrow Transplant</i> 2012;47:646-50.	10
Harvath L, Andersen BR. Defective initiation of oxidative in polymorphonuclear leukocytes. <i>N Engl J Med</i> 1979;300:1130-5.	1
Hattori H, Tsuruta S, Horikoshi Y, Amano K, Takashima Y, Sakashita K, et al. Successful human leukocyte antigen one antigen-mismatched related bone marrow transplantation in a 6-year-old boy with leukocyte adhesion deficiency syndrome. <i>Pediatr Int</i> 2001;43:306-9.	1
Hayward AR, Harvey BA, Leonard J, Greenwood MC, Wood CB, Soothill JF. Delayed separation of the umbilical cord, widespread infections, and defective neutrophil mobility. <i>Lancet</i> 1979;1:1099-101.	6
Hinze CH, Lucky AW, Bove KE, Marsh RA, Bleesing JH, Passo MH. Leukocyte adhesion deficiency type 1 presenting with recurrent pyoderma gangrenosum and flaccid scarring. <i>Pediatr Dermatol</i> 2010;27:500-3.	1
Hixson P, Smith C, Shurin SB, Tosi MF. Unique CD18 mutations involving a deletion in the extracellular stalk region and a major truncation of the cytoplasmic domain in a patient with leukocyte adhesion deficiency type 1. <i>Blood</i> 2004;103:1105-13.	1
Hogg N, Stewart MP, Scarth SL, Newton R, Shaw JM, Law SK, et al. A novel leukocyte adhesion deficiency caused by expressed but nonfunctional $\beta 2$ integrins Mac-1 and LFA-1. <i>J Clin Invest</i> 1999;103:97-106.	1
Hu TC, Wang LC, Chiang BL. Type 1 leukocyte adhesion deficiency complicated by the presence of idiopathic liver cirrhosis. <i>J Formosan Med Assoc</i> 2014;113:877-8.	1
Hung CH, Cheng SN, Hua YM, Wang CL, Chen YH, Yang KD. Leukocyte adhesion deficiency disorder: report of one case. <i>Acta Paediatr Taiwan</i> 1999;40:128-31.	1
Jabbari Azad F, Ardalan M, Hoseinpoor Rafati A, Sotoudeh S, Pourpak Z. Osteomyelitis in leukocyte adhesion deficiency type 1 syndrome. <i>J Infect Dev Ctries</i> 2010;4:175-8.	1

(continued)

TABLE E2. (Continued)

Reference	No. of cases
Jabado N, Le Deist F, Cant A, De Graeff-Meeders ER, Fasth A, Morgan G, et al. Bone marrow transplantation from genetically HLA-nonidentical donors in children with fatal inherited disorders excluding severe combined immunodeficiencies: use of two monoclonal antibodies to prevent graft rejection. <i>Pediatrics</i> 1996;98:420-8.	2
Jain S, Gozdziaik P, Morgan A, Burt RK. Remission of Crohn's disease after cord blood transplantation for leukocyte adhesion deficiency type 1. <i>Bone Marrow Transplant</i> 2013;48:1006-7.	1
Jasani BB, Nanavati R, Kabra N. Unusual neonatal presentation of type I leukocyte adhesion deficiency. <i>J Clin Neonatol</i> 2014;3:109-11.	1
Jothilakshmi K, Priva S, Matthai J. Leukocyte adhesion defect-1. <i>Indian Pediatr</i> 2008;45:507-9.	1
Kavehmanesh Z, Matinzadeh ZK, Amirjalali S, Torkaman M, Afsharpayman S, Javadipour M. Leukocyte adhesion deficiency: report of two family related newborn infants. <i>Acta Med Iran</i> 2010;48:273-6.	2
Kobayashi K, Fujita K, Okino F, Kajii T. An abnormality of neutrophil adhesion: autosomal recessive inheritance associated with missing neutrophil glycoproteins. <i>Pediatrics</i> 1984;73:606-10.	1
Kuijpers TW, van Lier RAW, Hamann D, de Boer M, Thung LY, Weening RS, et al. Leukocyte adhesion deficiency type 1 (LAD-1)/variant: a novel immunodeficiency syndrome characterized by dysfunctional β 2 integrins. <i>J Clin Invest</i> 1997;100:1725-33.	1
Levy-Mendelovich S, Rechavi E, Abuzaitoun O, Vernitsky H, Simon AJ, Lev A, et al. Highlighting the problematic reliance on CD18 for diagnosing leukocyte adhesion deficiency type 1. <i>Immunol Res</i> 2016;64:476-82.	10
Li L, Jin YY, Cao RM, Chen TX. A novel point mutation in CD18 causing leukocyte adhesion deficiency in a Chinese patient. <i>Chin Med J (Engl)</i> 2010;123:1278-82.	1
Madkaikar M, Currimbhoy Z, Gupta M, Desai M, Rao M. Clinical profile of leukocyte adhesion deficiency type I. <i>Indian Pediatr</i> 2011;49:43-5.	7
Madkaikar M, Italia K, Gupta M, Chavan S, Mishra A, Rao M, et al. Molecular characterization of leukocyte adhesion deficiency-I in Indian patients: identification of 9 novel mutations. <i>Blood Cells Mol Dis</i> 2015;54:217-23.	30
Majorana A, Notarangelo LD, Savoldi E, Gastaldi G, Lozada-Nur F. Leukocyte adhesion deficiency in a child with severe oral involvement. <i>Oral Surg Oral Med Oral Pathol Oral Radiol Endod</i> 1999;87:691-4.	1
Malawista SE, de Boisfleury Chevance A, Boxer LA. Random locomotion and chemotaxis of human blood polymorphonuclear leukocytes from a patient with leukocyte adhesion deficiency-1: normal displacement in close quarters via chimneying. <i>Cell Motil Cytoskeleton</i> 2000;46:183-9.	1
Mancias C, Infante AJ, Kamani NR. Matched unrelated donor bone marrow transplantation in leukocyte adhesion deficiency. <i>Bone Marrow Transplant</i> 1999;24:1261-3.	1
Marsili M, Lougaris V, Lucantoni M, Di Marzio D, Baronio M, Vitali M, et al. Successful anti-TNF- α treatment in a girl with LAD-1 disease and autoimmune manifestations. <i>J Clin Immunol</i> 2014;34:788-91.	1
Martinez SA, McNellis EL, Weber PC, Adkins WY. Bilateral acute coalescent mastoiditis in an immunocompromised infant with a rare leukocyte adhesion deficiency. <i>Otolaryngol Head Neck Surg</i> 1999;120:926-8.	1
Mathew EC, Shaw JM, Bonilla FA, Law SK, Wright DA. A novel point mutation in CD18 causing the expression of dysfunctional CD11/CD18 leucocyte integrins in a patient with leukocyte adhesion deficiency (LAD). <i>Clin Exp Immunol</i> 2000;121:133-8.	1
Miedema F, Tetteroo PA, Terpstra FG, Keizer G, Roos M, Weening RS, et al. Immunologic studies with LFA-1- and Mo1-deficient lymphocytes from a patient with recurrent bacterial infections. <i>J Immunol</i> 1985;134:3075-81.	2
Mogica-Martinez, Lopez-Duran JL, Canseco-Raymundo MR, Becerril Angeles M. Leukocyte adhesion deficiency syndrome: case report. <i>Rev Alerg Mex</i> 1999;46:140-4.	1
Mortezae FT, Esmali B, Badalzadeh M, Ghadami M, Fazlollahi MR, Alizade Z, et al. Investigation of ITGB2 gene in 12 new cases of leukocyte adhesion deficiency-type 1 revealed four novel mutations in Iran. <i>Arch Iran Med</i> 2015;18:760-4.	12
Moutsopoulos N, Konkel J, Sarmadi M, Eskin MA, Wild T, Dutzan N, et al. Defective neutrophil recruitment in leukocyte adhesion deficiency type I disease causes local IL-17-driven inflammatory bone loss. <i>Sci Transl Med</i> 2014;6:229ra40.	5
Naess A, Sjrursen H, Leegaard J. Leukocyte adhesion deficiency in a Norwegian boy. <i>Scand J Infect Dis</i> 1999;31:600-2.	1

(continued)

TABLE E2. (Continued)

Reference	No. of cases
Nagendran J, Prakash C, Anandakrishna L, Gaviappa D, Ganesh D. Leukocyte adhesion deficiency: a case report and review. <i>J Dent Child (Chic)</i> 2012;79:105-10.	1
Nauseef WM, De Alarcon P, Bale JF, Clark RA. Aberrant activation and regulation of the oxidative burst in neutrophils with Mol glycoprotein deficiency. <i>J Immunol</i> 1986;137:636-42.	1
Nezelof C. Chronic omphalitis in a 4-month-old girl. <i>Pathol Res Pract</i> 1991;187:334-7.	1
Niethammer D, Dieterle U, Kleihauer E, Wildfeuer A. An inherited defect in granulocyte function: impaired chemotaxis, phagocytosis and intracellular killing of microorganisms. <i>Helv Paediatr Acta</i> 1976;30:537-41.	4
Paller AS, Nanda V, Spates C, O'Gorman M. Leukocyte adhesion deficiency: recurrent childhood skin infections. <i>J Am Acad Dermatol</i> 1994;31:316-9.	1
Parvaneh N, Mamishi S, Rezaei A, Rezaei N, Tamizifar B, Parvaneh L, et al. Characterization of 11 new cases of leukocyte adhesion deficiency type 1 with seven novel mutations in the ITGB2 gene. <i>J Clin Immunol</i> 2010;30:756-60.	11
Patiroglu T, Akar HH, Unal E, Ozdemir MA, Karakukcu M. Hematopoietic stem cell transplant for primary immunodeficiency diseases: a single-center experience. <i>Exp Clin Transplant</i> 2017;15:337-43.	1
Pollard AJ, Heale JP, Tsang A, Massing B, Speert DP. Nonopsonic phagocytosis of <i>Pseudomonas aeruginosa</i> : insights from an infant with leukocyte adhesion deficiency. <i>Pediatr Infect Dis J</i> 2001;20:452-4.	1
Qasim W, Cavazzana-Calvo M, Davies G, Davis J, Duval M, Eames G, et al. Allogeneic hematopoietic stem cell transplantation for leukocyte adhesion deficiency. <i>Pediatrics</i> 2009;123:836-40.	36
Rawat A, Singh S, Sharma D, Suri D, Rajwanshi A, Etzioni A. Amyloidosis in a child with leukocyte adhesion deficiency type-1: an unusual association. <i>Indian J Pediatr</i> 2011;78:1546-8.	1
Rivera-Matos IR, Ratika R, Mariscalco MM, Elder FF, Dreyer SA, Cleary TG. Leukocyte adhesion deficiency mimicking Hirschsprung disease. <i>J Pediatr</i> 1995;127:755-7.	1
Roberts MW, Atkinson JC. Oral manifestations associated with leukocyte adhesion deficiency: a five-year case study. <i>Pediatr Dent</i> 1990;12:107-11.	1
Roos D, Meischl C, deBoer M, Simsek S, Weening RS, Sanal O, et al. Genetic analysis of patients with leukocyte adhesion deficiency: genomic sequencing reveals otherwise undetectable mutations. <i>Exp Hematol</i> 2002;30:252-61.	8
Ross GD. Clinical and laboratory features of patients with an inherited deficiency of neutrophil membrane complement receptor type 3 (CR3) and the related membrane antigens LFA-1 and p150,95. <i>J Clin Immunol</i> 1986;6:107-13.	4
Ross GD, Thompson RA, Walport MJ, Springer TA, Watson JV, Ward RH, et al. Characterization of patients with an increased susceptibility to bacterial infections and a genetic deficiency of leukocyte membrane complement receptor type 3 and the related membrane antigen LFA-1. <i>Blood</i> 1985;66:882-90.	1
Shaw JM, Al-Shamkhani A, Boxer LA, Buckley CD, Dodds AW, Klein N, et al. Characterization of four CD18 mutants in leukocyte adhesion deficient (LAD) patients with differential capacities to support expression and function of the CD11/CD18 integrins LFA-1, Mac-1 and p150,95. <i>Clin Exp Immunol</i> 2001;126:311-8.	3
Simon A, Pillai S, Raghupathy P, Chandy M. Leucocyte adhesion deficiency-1. <i>Indian Pediatr</i> 2002;39:963-6.	1
Simon AJ, Lev A, Wolach B, Gavrieli R, Amariglio N, Rosenthal E, et al. The effect of gentamicin-induced readthrough on a novel premature termination codon of CD18 leukocyte adhesion deficiency patients. <i>PLoS One</i> 2010;5:e13659.	2
Sivathanu S, Sampath S, Sridhar I. Recurrent omphalitis and nonhealing ulcers in a 7-month-old girl. <i>Pediatr Rev</i> 2016;37:491.	1
Sligh JE, Hurwitz MY, Zhu C, Anderson DC, Beaudet AL. An initiation codon mutation in CD18 in association with the moderate phenotype of leukocyte adhesion deficiency. <i>J Biol Chem</i> 1992;267:714-8.	1
Strickler A, Gallo S, King A, Rosenzweig SD. Leucocyte adhesion deficiency type 1 with developmental delay secondary to CMV infection and filiation questions. <i>BMJ Case Rep</i> 2015;2015:pii: bcr2014208973.	1
Suliaman F, Jabbar MA. The association of leukocyte adhesion defect type I and persistent hyperinsulinemic hypoglycemia of infancy in a Saudi Arabian family. <i>Pediatr Hematol Oncol</i> 2002;19:429-32.	2

(continued)

TABLE E2. (Continued)

Reference	No. of cases
Takahashi D, Nagatoshi Y, Saito Y, Inagaki J, Nagayama J, Shinkoda Y, et al. Unrelated bone marrow transplantation using a reduced intensity-conditioning regimen in leukocyte adhesion deficiency. <i>Bone Marrow Transplant</i> 2006;37:807-8.	1
Thakur H, Sodani R, Chandra J, Singh V. Leukocyte adhesion defect type 1 presenting with recurrent pyoderma gangrenosum. <i>Indian J Dermatol</i> 2013;58:158.	1
Thomas C, Le Deist F, Cavazzana-Calvo M, Benkerrou M, Haddad E, Blanche S, et al. Results of allogeneic bone marrow transplantation in patients with leukocyte adhesion deficiency. <i>Blood</i> 1995;86:1629-35.	14
Thompson RA, Candy DCA, McNeish AS. Familial defect of polymorph neutrophil phagocytosis associated with absence of a surface glycoprotein antigen (OKMI). <i>Clin Exp Immunol</i> 1984;58:229-36.	2
Tipu HN. Leukocyte adhesion deficiency type I: a rare primary immunodeficiency disorder. <i>Pediatr Allergy Immunol</i> 2017;28:303-5.	2
Tipu HN, Tahir A, Ahmed TA, Hazir T, Waqar MA. Leukocyte adhesion defect. <i>J Pak Med Assoc</i> 2008;58:643-5.	1
Tone Y, Wada T, Shibata F, Toma T, Hashida Y, Kasahara Y, et al. Somatic revertant mosaicism in a patient with leukocyte adhesion deficiency type 1. <i>Blood</i> 2007;109:1182-4.	1
Toomarian L, Hashemi N. Periodontal manifestation of leukocyte adhesion deficiency type I. <i>Arch Iran Med</i> 2010;13:355-9.	1
Uzel G, Tng E, Rosenzweig SD, Hsu AP, Shaw JM, Horwitz ME, et al. Reversion mutations in patients with leukocyte adhesion deficiency type-1 (LAD-1). <i>Blood</i> 2008;111:209-18.	3
Van De Kerkhof PCM, Weemaes CMR. Skin manifestations in congenital deficiency of leukocyte-adherence glycoproteins (CDLG). <i>Br J Dermatol</i> 1990;123:395-401.	3
Vasconcelos Dde M, Beitler B, Martinez GA, Pereira J, Amigo Filho JU, Klautau GB, et al. CD18 deficiency evolving to megakaryocytic (M7) acute myeloid leukemia: case report. <i>Blood Cells Mol Dis</i> 2014;53:180-4.	1
Vasquez-De Kartzow R, Jesam C, Nehgme V, Vargas F, Sepúlveda C. Leukocyte adhesion deficiency syndrome: report on the first case in Chile and South America. <i>Sao Paulo Med J</i> 2012;130:263-6.	1
Webber EC, Church J, Rand TH, Shah AJ. Leukocyte adhesion deficiency in a female patient without delayed umbilical cord separation. <i>J Paediatr Child Health</i> 2007;43:406-8.	1
Weening RS, Bredius RGM, Vomberg PP, van der Schoot CE, Hoogerwerf M, Roos D. Recombinant human interferon- γ treatment in severe leukocyte adhesion deficiency. <i>Eur J Pediatr</i> 1992;151:103-7.	1
Weening RS, Roos D, Weemaes CM, Homan-Müller JW. Defective initiation of the metabolic stimulation in phagocytizing granulocytes: a new congenital defect. <i>J Lab Clin Med</i> 1976;88:757-68.	2
Weisman SJ, Berkow RL, Plautz G, Torres M, McGuire WA, Coates TD, et al. Glycoprotein-180 deficiency: genetics and abnormal neutrophil activation. <i>Blood</i> 1985;65:696-704.	1
Wright AH, Douglass WA, Malcolm Taylor G, Lau YL, Higgins D, Davies KA, et al. Molecular characterization of leukocyte adhesion deficiency in six patients. <i>Eur J Immunol</i> 1995;25:717-22.	6
Yamazaki-Nakashimada M, Maravillas-Montero JL, Berron-Ruiz L, López-Ortega O, Ramírez-Alejo N, Acevedo-Ochoa E, et al. Successful adjunctive immunoglobulin treatment in patients affected by leukocyte adhesion deficiency type 1 (LAD-1). <i>Immunol Res</i> 2015;61:260-8.	2
Yassaee VR, Hashemi-Gorji F, Boosaliki S, Parvaneh N. Mutation spectra of the ITGB2 gene in Iranian families with leukocyte adhesion deficiency type 1. <i>Hum Immunol</i> 2016;77:191-5.	19
Yoshimoto A, Hashii Y, Kashiwagi H, Koizumi M, Tokimasa S, Fujisaki H, et al. Successful allogeneic stem cell transplant for leukocyte adhesion deficiency using an adjusted busulfan-containing regimen. <i>Pediatr Transplant</i> 2007;11:453-5.	1

Note. A total of 323 LAD-I cases were evaluated and included in the database, identified in the 107 publications listed in the table.

*Because the 10 cases noted here were described in more than 1 publication, the sum of cases in the table is 333.

TABLE E3. Infections specified (by LAD-I severity)*

Infection	CD18 <2% (n = 85)		CD18 ≥2% (n = 69)	
	n	%	n	%
Otitis media	23	27	25	36
Respiratory tract including pneumonia	33	39	16	23
Sepsis	25	29	17	25
Periodontal including gingivitis and oral ulcers	20	24	36	52
Perianal skin infections	17	20	10	14
Necrotic skin ulcers	11	13	8	12

*Includes conditions reported as >10% of specified infections.

TABLE E4. Umbilical cord complications by neutrophil CD18 expression (LAD-I severity)

Umbilical cord complications	LAD-I severity	
	CD18 <2% (n = 110)	CD18 ≥2% (n = 81)
Yes	92 (84%)	47 (58%)
No	18 (16%)	34 (42%)

Note. Umbilical cord complications include delayed cord separation and omphalitis. Umbilical cord complication information was available for 110 of 135 patients with CD18 <2% and 81 of 130 patients with CD18 ≥2%.

TABLE E5. Umbilical cord complications and 2-y mortality in LAD-I with CD18 <2%

Umbilical cord complications	Death before 24 mo	Alive at 24 mo
Complications	28	8
No complications	0	6

Umbilical cord complications include delayed cord separation and omphalitis. Table includes information for 42 patients from whom information regarding umbilical cord complications was available, and for whom follow-up to age 2 y (or death before the age 2 of y) was provided.

TABLE E6. LAD-I cases with CD18 >30% and at least 1 CD11 moiety <2%

Patient	Pheno	Sex	Mutation	Loc	Type	CD18%	CD11a%	CD11b%	CD11c%	Nation	Year of publication
Levi-Mendel-ovich 2016-2	M	Male	c.n.C562T; p.R188X	Exon 6	Nonsense	44	1	93	55	Israel	2016
Levi-Mendel-ovich 2016-5	M	Female	10-bp deletion, c.n.119-GGCCCGGCTG	Exon 3	Frame shift	51	0	64	0	Israel	2016
Levi-Mendel-ovich 2016-7	M	Female	1-bp deletion, c.n.1096-G	Exon 10	Frame shift	77	0	94	0	Israel	2016
Levi-Mendel-ovich 2016-8	M	Male	1-bp deletion, c.n.1096-G	Exon 10	Frame shift	90	0	94	98	Israel	2016
Levi-Mendel-ovich 2016-9	M	Male	c.850G>A, G284S	Exon 7	Missense	55	0	0	0	Israel	2016
Mortezae 2015-8	NS	Female	c.691G>C	Exon 6	Missense	42	2.4	15	1.9	Iran	2015
Esmaeili 2014-1	NS	Female	c.382G>A; p. Asp128Asn	Exon 5	Missense	40	11	1.5	5	Iran	2014
Hinze 2010-1	NS	Male	314T>C	NS	Missense	40	0	1	0	United States	2010

Loc, Location on *ITGB2* gene; *Pheno*, phenotype per investigator.

TABLE E7. Allogeneic HSCT

HSCT type	n	Phenotypic correction		Engraftment failure		Subsequent HSCT		HSCT-related mortality	
		n	%	n	%	n	%	n	%
MSD	36	30	83	2	6	2	6	4	11
MFD	10	8	80	0	—	0	—	2	20
MMFD	2	2	100	0	—	0	—	0	—
MUD	25	19	76	0	—	2	8	6	24
Haplo	22	11	50	4	18	12	55	7	32
CB	6	4	67	2	33	3	50	0	—

CB, Cord blood; *Haplo*, haploidentical donor; *MFD*, matched family donor; *MMFD*, mismatched family donor; *MSD*, matched sibling donor; *MUD*, matched unrelated donor; *NS*, not stated.

Note. Outcomes were available for 101 of 125 patients reported to have received HSCT, of which LAD-I severity was as follows: severe, n = 46; moderate, n = 11; not specified, n = 44. Phenotypic correction is defined as a reversal of the underlying immunodeficiency.